

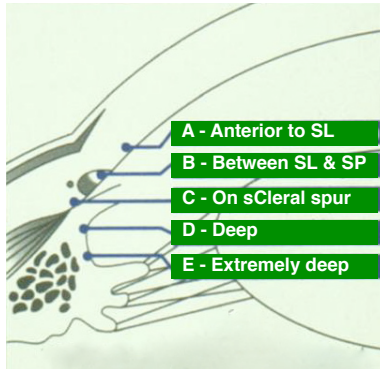
ADLS

Angle Damage Likelihood Scale

Developed by dr. George Spaeth
President of Glaucoma Services, Wills Eye Hospital

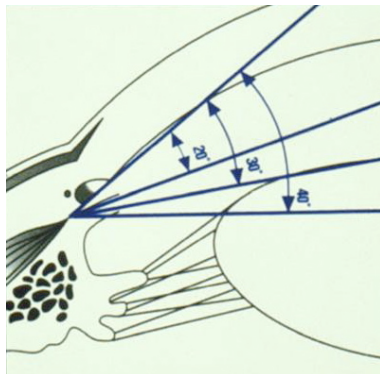


www.wagnersyndrome.eu



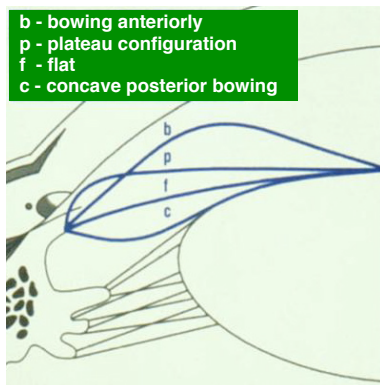
1 Iris insertion

- A Anterior to Schwalbe's line (SL)
- B Between SL and scleral spur
- C On the sCleral spur
- D Deep: ciliary body visible
- E Extremely deep: > 1 mm ciliary body



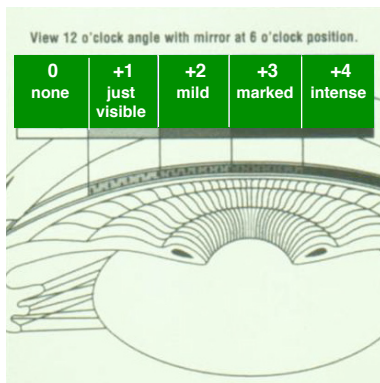
2 Angle of interior chamber

- 20% narrow
- 30% wide
- 40% wide



3 Curvature of iris

- b bowing anteriorly
- p plateau configuration
- f flat
- c concave posterior bowing



4 Pigmentation Trabecular Meshwork

- 0 none
 - +1 just visible
 - +2 mild
 - +3 marked
 - +4 intense
- (View 12 o'clock angle with mirror at 6 o'clock position)

Please grade the angle like this: **C30%b+2**, meaning:
the iris insertion is on the scleral spur, with an angle of 30%, curvature is bowing anteriorly,
pigmentation of the trabecular meshwork is mild.